

# RADIOGRAPHIC EVALUATION AND SOFT PALATE DIVERTICULECTOMY OF IMPACTED DULAA IN TWO CAMELS (*Camelus dromedarius*)

Ruchi Patwa, Mahendra Tanwar, P. Bishnoi, A.K. Bishnoi, Shivangi Diwedi and Balkrishan Yadav

Department of Veterinary Surgery and Radiology, College of Veterinary and Animal Science,  
Rajasthan University of Veterinary and Animal Sciences, Bikaner-334 001, Rajasthan

## ABSTRACT

Two camels of impacted dulaa (soft palate diverticulum) were presented with a history of inability of soft palate protrusion, anorexia and dyspnoea. Clinical examination with radiographic evaluation was done. Clinical examination of throat region revealed pain and dyspnoea on palpation. Lateral radiographic view of cranial cervical region was taken and radiograph showed increased radiodensity of irregular soft tissue with scattered gaseous radiolucency. Complete clinical and radiographic examination revealed accumulation of food and pus in the soft palate and surgical resection of impacted dulaa was planned. Soft palate diverticulectomy was done by intraoral approach under general anaesthesia. Both the animals recovered uneventfully. The conclusion of the clinical case report was that, in case of impacted dulaa, pharyngeal region radiography helps delineating the larynx, proximal trachea, oesophagus, naso and oropharynx. Enlarged size and radiodense dulaa (impacted by feed material) were seen radiographically and helped planning the surgery.

**Key words:** *Camelus dromedarius*, impacted dulaa, radiographic evaluation, soft palate

The soft palate diverticulum (dulaa) is an oroventral projection of soft palate and is injured by the camel's own canine teeth or by other camels while fighting, or by thorns and wires commonly during breeding season. The signs may include oedema, perforation and haematoma depending upon the causal agent and degree of trauma (Gahlot and Chouhan, 1992; Tanwar *et al*, 2016; Kumar *et al*, 2017). The food sometimes becomes impacted in the dulaa. The size of impacted dulaa may sometimes go up to the size of a football. The mass is very hard to touch. In the case of larger mass, the resection of the organ is required. Tracheotomy is also before resection (Choudhry *et al*, 2017). Clinical findings and surgical exteriorisation of dulaa has been reported following various types of dulaa injuries (Sadan and El-Shafaey, 2020). Radiography is scarcely reported for the diagnosis of injured dulaa in camels. The present study described radiographic evaluation of impacted dulaa and its surgical resection in two dromedary camels.

## Materials and Methods

Two camels aged 7 and 12 years, were presented at Veterinary Clinical Complex, Rajasthan University of Veterinary and Animal Sciences,

Bikaner, with the history of anorexia, dyspnoea, inability of dulaa protrusion and swelling at cervical region. Clinical examination along with aseptic fine needle aspiration of swollen area of throat region and radiographic evaluation was done. Clinical examination revealed pain and swelling on palpation and while straightening the neck (Fig 1). Complete clinical and radiographic examination revealed accumulation of food and pus in the soft palate and surgical resection of impacted dulaa or soft palate diverticulectomy was planned. Animals were kept off feed and water for 24 hours. Camels were restrained in sternal recumbency and surgical procedure was performed under general anaesthesia including (xylazine @ 0.2 mg /kg and ketamine @ 1mg / kg body weight). After induction of anaesthesia, a gag was placed between the upper and lower jaws and an attempt was made to pull the soft palate out of the oral cavity using a hook while the assistant was instructed to massage the proximal area of the neck with the palm towards the oral cavity and to squeeze the neck region but all went in vain. The surgeon's hand was inserted inside the oral cavity till the pharyngeal region and the distended soft palate was pulled out manually after removing the adhesions by holding the organ with a towel.

SEND REPRINT REQUEST TO RUCHI PATWA [email: ruchipatwa611@gmail.com](mailto:ruchipatwa611@gmail.com)

The exteriorised soft palate was found gangrenous and the pus was drained out along with the feed material (Fig 2A&B). The soft palate was excised using long straight Mayo scissors by pulling it outwards and twisting it with a towel. The oral cavity was flushed daily with light potassium paramanganate solution for 5-7 day. Postoperatively streptopenicillin 7.5 g for 5 days and meloxicam @ 0.3 mg/kg body weight for 3 days were administered intramuscularly. The camels were given soft fodder for two weeks.

## Results and Discussion

Clinical signs, dyspnoea, i.e. pain and swelling were suggestive of severe inflammation throat region, even were straightening the neck. Aseptic fine needle aspiration of swelling at throat region revealed straw coloured fluid which was suggestive of presence of inflammatory fluid together with trapped feed. Lateral radiograph of cranial cervical region in both cases showed increased radiodensity of irregular soft tissue with scattered gaseous radiolucency close the epiglottis (Fig 3). Oral cavity examination under general anaesthesia found impacted soft palate with feed material. Soft palate was found gangrenous and contained pus (Fig 4). Soft palate diverticulectomy was performed and the camels recovered uneventfully (Fig 5).

Dulaa gets injured with its own teeth, biting of other camel and by external trauma (Gahlot, 2000 and Tanwar *et al*, 2016). Injury occurs commonly during rut season and injured dullla either hangs out or remain entrapped *in situ*. The affected animals usually show discomfort when swallowing, dysphagia, dyspnoea and are unable to extrude the dulaa due to lacerated wounds, gangrene, ulcers, abscesses or impaction with feed material (Ramadan, 2013). In animals of present study, dysphagia, dyspnoea and pain on palpation at throat region and while



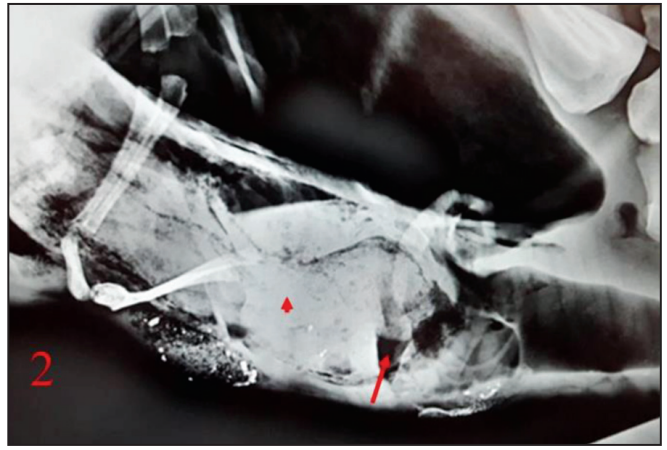
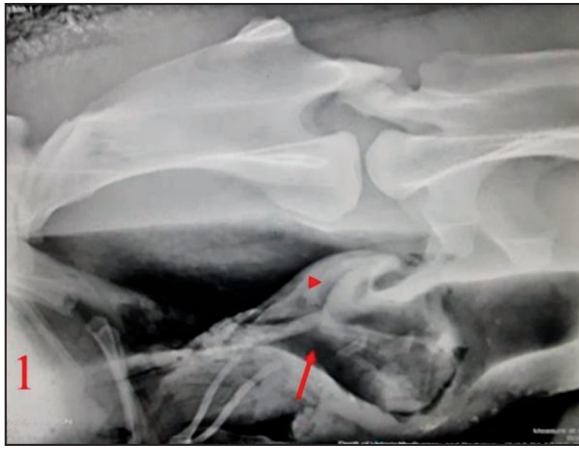
Fig 1. Swelling and pain on palpation and while straightening of neck.

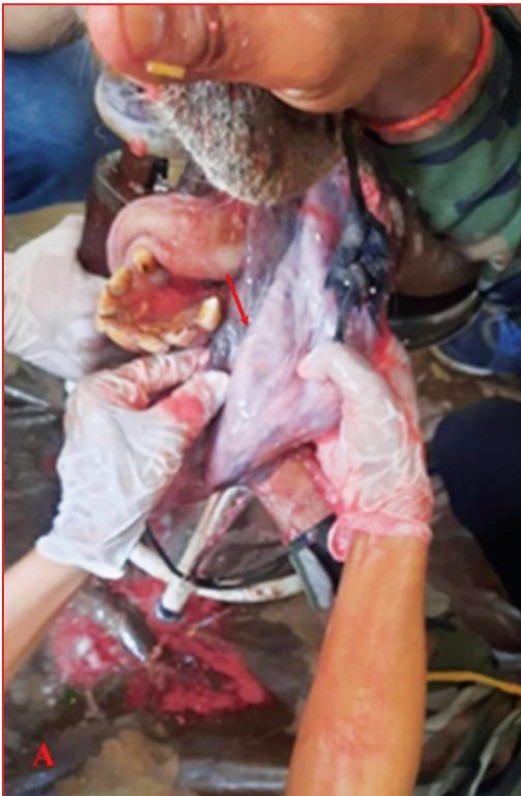

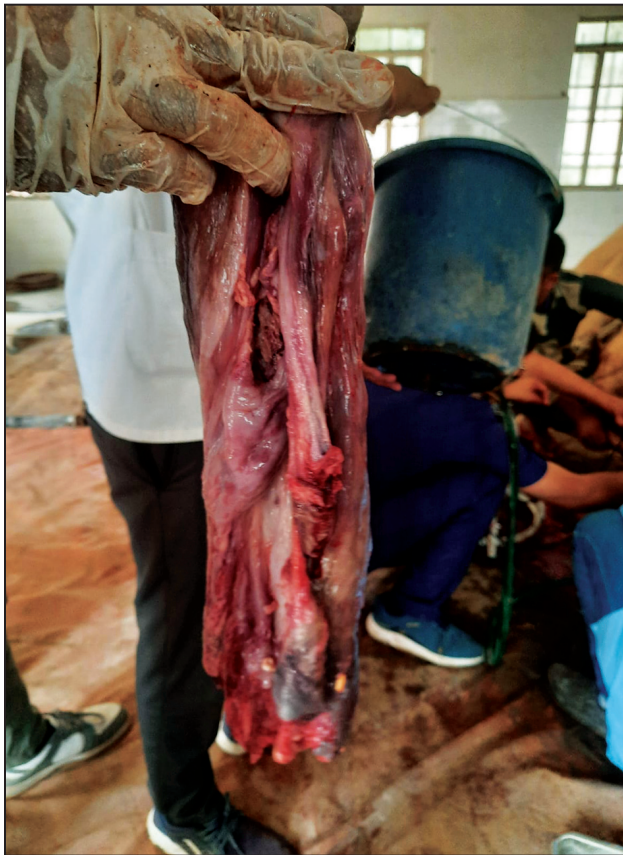Fig 2A. Gangrenous soft palate (arrow).



Fig 2B. Pus drained into oral cavity.



**Fig 3.** Lateral radiographic view of cranial cervical region was taken and radiograph showed increased radiodensity of irregular soft tissue with scattered gaseous radiolucency (arrow) in the camels.



**Fig 4.** Gangrenous soft palate.



**Fig 5.** Surgical wound after 15 days of excision of soft palate.

straightening the neck were observed. Rollefson *et al* (2001) also reported inability of dulaa ballooning as it remains entrapped condition or stays hanging outside the mouth. In present case report, the dulaa was entrapped and camel couldn't take feed and water in both the cases.

Radiography can be used for detection of impacted dulaa in pharyngeal region when the dulaa cannot be extruded by the animal. However, when

the dulaa gets impacted with feed particles its size and density increases. It is pushed caudally to press against the epiglottis thus interfering with breathing (Ramadan, 2013). In present clinical case report dulaa was impacted with feed material and pus which appeared as radiopaque soft tissue mass in cranial cervical region radiography (Fig 3). Sadan *et al* (2023) reported that radiography is advanced non-invasive diagnostic technique for the diagnosis of oesophageal

obstruction in addition to exploratory surgery to confirm the condition. Dorsoventral and lateromedial standard radiographs of affected camels were obtained under light sedation and radiographs were subjectively interpreted before surgical interventions. Moreover, successful surgical resection of the dulaa could be used as curative treatment of such disorders in camels (Sadan *et al*, 2020).

Ramadan (2013) also secured camels in sternal position and sedated with 2% xylazine hydrochloride (0.2 mg/kg body weight) together with 10% ketamine hydrochloride at the dose of 1 mg/kg body weight given, intravenously for soft palate resection (Ramadan, 2013) and local infiltration analgesia using lidocaine HCL 2% which was infiltrated at the root of the dulaa (Al-Sobayil and Ahmed, 2011; Ramadan, 2013). Similarly, in present case report xylazine @ 0.2 mg /kg body weight and ketamine @ 1mg / kg body weight were used in soft palate diverticulectomy without local anaesthesia in both cases.

In present case report resection of soft palate was performed by intraoral route which is simple, less time consuming and doesnot subject the animal to the risk of general anaesthesia. However, Ramadan (2013) described resection of soft plate by pharyngostomy, where in dulla was pulled out through pharyngeal opening between intermandibular space. A temporary tracheotomy tube or a suitable endotracheal tube was inserted down the trachea in pharyngostomy approach.

In present study, soft palate found was gangrenous and impacted with feed material. Similar injuries of soft palate leading to gangrene and haematoma of the soft palate have been reported previously (Gahlot and Chouhan, 1992; Sadan and El-Shafaey, 2020).

In present clinical case report was dulaa resected after pulling the soft palate out with a cotton cloth and two long artery forceps were used to hold and crush the major blood vessels close to the origin of the dulaa. A purse string suture using polydioxanone no. 2 was applied approximately 1 cm distal to the location of the artery forceps. The dissection was performed distal to the suture. The

dulaa was removed and the stump was closed by cushioning suture pattern using polydioxanone no. 2. Al-Sobayil and Ahmed (2011) stated that in some cases, interrupted, overlapping horizontal mattress suture pattern was used before amputation and the wound was further closed by simple continuous sutures. The severed edges were cauterised with strong potassium permanganate solution. Haemostasis occurred in couple of minutes (Gharu *et al*, 2016).

## Conclusion

The impacted dulaa can be diagnosed early with radiography which can help in deciding the extent of pathology before proceeding for its surgery.

## References

- Al-Sobayil FA and Ahmed AF. Surgery of the injured dulla in dromedary camels (*Camelus dromedarius*). Iranian Journal of Veterinary Surgery. 2011; 6(1-2):17-22.
- Chaudhry Z. Camel and its Disease. 1<sup>st</sup> Ed. Lap Lambert Academic Publishing, Mauritius. 2017; pp 6-42.
- Gahlot TK and Chouhan DS. Camel Surgery. Gyan Prakash Mandir, Bikaner, India. 1992; pp 47-52.
- Gahlot TK. Selected Topics on Camelids. The Camelid Publishers. Bikaner, India. 2000; 318-319.
- Gharu S, Singh D, Khosa JS, Kachwaha, K, Bamniya MK Qureshi SM and Gahlot TK. Surgical management of entrapped soft palate in camels (*Camelus dromedarius*). Indian Veterinary Journal. 2016; 93(11):67-68.
- Kumar P, Purohit NR and Gahlot TK. Clinical study on surgical affections of soft palate in camels (*Camelus dromedarius*). Intas Polivet. 2017; 18(1):222-225.
- Ramadan RO. Surgery of the dulaa in the camel (*Camelus dromedarius*). Journal of Agricultural and Marine Sciences. 2013; 18:25-29.
- Rollefson KI, Mundy P and Mathias E. A Field Manual of Camel Diseases. ITDG Publishing. London, UK. 2001; pp 106-107.
- Sadan M and El-Shafaey ES. Diagnosis and surgical repair of soft palate (dulla) injuries in camel (*Camelus dromedarius*). Journal of Camel Health. 2020; 1(2):38-42.
- Sadan M, El-Khodery S, Almatroodi S, Alsobayi F and El-Shafaey ES (2023). Diagnosing and treating oesophageal obstruction in camels (*Camelus dromedarius*). Veterinary World. 2023; 16(4):735.
- Tanwar Mahendra, Bishnoi P, Palecha S, Jhirwal SK and Singh S. Soft palate excision in camel (*Camelus dromedarius*)-report of 8 cases. Intas Polivet. 2016; 17(2):567-568.